

Evaluation of Efficacy and Safety of Talekt Syrup in Atopic Dermatitis

UMA AGARWAL, PRASAD S.R., MITRA S.K.

ABSTRACT

Atopic dermatitis is a commonly encountered skin inflammation with variable etiology and clinical presentation. Available treatment options for management have a major drawback of failure in preventing high recurrence. This study was planned to evaluate the clinical efficacy and safety of Talekt syrup in atopic dermatitis.

This was an open, non-comparative clinical trial. A total of 100 patients, who were refractory to conventional treatment and who were willing to give informed consent, were included in the study. Pregnant and lactating women, children below 14 years of age, patients with severe systemic illness, and patients with genetic disorders were excluded from the study. At the initial visit, a detailed medical history, with special emphasis on family history of atopy, history of known contacts and treatment history was obtained from all patients. Duration of symptoms, onset status, recurrence, anatomical distribution, initiation of lesion, pain, and presence of any additional signs was noted. The details of present episode were recorded in terms of onset, progression of lesion, relieving factors and seasonal exacerbation. The local examination included details of the pattern and morphology of the lesion. Each symptom was given equal weightage on a specially designed score scale and the total score was calculated before and after drug treatment.

The patients were reviewed for 12 weeks and score evaluation was recorded at the end of each week and a complete clinical and hematological examination was done at the end of the 12th week. The predefined primary endpoints were reduction in the mean scores of dermal edema, pruritus, papules, vesicles, urticaria, tenderness, epidermal thickening, and pigmentation. The predefined secondary endpoints were incidences of short- and long-term adverse events and compliance to the drug treatment.

The mean score for dermal edema, pruritus, papules, vesicles, urticaria, tenderness, epidermal thickening, and pigmentation reduced significantly at the end of 12-week period. There were no clinically significant adverse events reported and observed during the entire study period. Therefore, it may be concluded that Talekt syrup is clinically safe and effective in the management of atopic dermatitis.

INTRODUCTION

Atopic dermatitis (AD) is a common, chronic inflammatory skin condition that frequently develops in infancy or early childhood¹. Epidemiologic studies have shown that AD affects between 10% and 20% of children and between 1% and

3% of adults^{2,3}. In 85% of cases, the first signs and symptoms of AD appear before age 5 years⁴. Atopic dermatitis is characterized by episodic flares of pruritus, erythema, excoriation, and papulation that can be initiated by a variety of environmental and allergen triggers⁵.

During the acute stage, serous or sanguineous ulcerations, vesicles and eczematous base are present. In the sub-acute stage, the skin is dry and eczematous without the presence of exudates. In the chronic stage of the disease, there is thickening of the corneous extract, scarification and lichenization⁶.

Signs classified as major may also be present, such as xerosis,

ichthyosis, accentuation of the palmar lines/creases, periauricular and perioral fissures, exfoliation of the scalp, white dermatographism, sudoresis, and stigmas such as infra-orbital Dennie-Morgan folds and Hertoghe sign. The diagnosis for atopic dermatitis is essentially clinical⁷.

Talekt Syrup is a polyherbal formulation indicated for management of AD and it contains extracts of *Azadirachta indica*, *Tinospora cordifolia*, *Embelia ribes*, *Eclipta alba*, *Andrographis paniculata*, *Curcuma longa*, *Cassia fistula*, and Triphala. This study was planned to evaluate the efficacy and safety of Talekt syrup in atopic dermatitis.

Dr. Uma Agarwal, M.B.B.S., F.R.S.T.M.&H. (London), M.R.S.H. (London), M.I.P.H.A., M.A.I.M.S., F.A.I.M.S., M.CH. (MSA SMS), Dio. Derma (SASMS), Dip. Allergology (SASSMS), F.I.A.M.S.
Medical Officer to School of Tropical Medicine, Kolkata, India.
Dr. S.R. Prasad, M.D.,
Medical Advisor
Dr. S.K. Mitra, M.D.,
Executive Director
R&D Center, The Himalaya Drug Company, Bangalore - 562 123, India.

Specially contributed to "The Antiseptic"
Vol 104 No 12 & P: 619 - 624

PATIENTS AND METHODS

A total of 100 pediatric and adult patients, with clinical symptoms of atopic dermatitis, were included in the study.

Inclusion criteria

Clinically diagnosed patients of atopic dermatitis, who were refractory to conventional treatment and who were willing to give informed consent, were included in the study.

Exclusion criteria

Pregnant and lactating women, children below 3 years of age, patients with severe systemic illness, and patients with genetic disorders were excluded from the study.

Study procedure

At the initial visit, a detailed medical history, with special emphasis on family history of atopy, history of known contacts (irritants: cosmetics, perfumes and deodorants; clothing: synthetic, wool; rubber and plastic objects; clips, buttons, elastic, leather, plants; foods: egg, shellfish, citrus fruits; drugs: antibiotics, antiseptics, local anesthetics; metals: jewelry, prosthesis, beryllium; fluorescent light, wood, toys; and others: cement, chemicals, insecticides), and treatment history (drugs and impact of treatment) was obtained from all patients. Duration of symptoms (6 months/1 year), onset status (acute/gradual onset), recurrence, anatomical distribution (generalized/localized), initiation of lesion (papule/urticaria/pinpoint hemorrhage), pain (tenderness/numbness), and presence of any additional signs (blisters/pustules) was also noted.

The details of present episode was recorded in terms of onset (sudden, gradual and exacerbation of pre-existing lesions), progression of the lesion (progressive, recurrent or static), relieving factors (work absenteeism, home rest or any other), and seasonal exacerbation was recorded. In all patients, a thorough systemic examination was done, which was followed by a detailed local examination of the involved area. Local examination included details of the pattern of the lesion (localized, generalized, unilateral, bilateral, or photoexposed) and morphology of the

lesion (epidermal thickening, pruritus, papules, vesicles, urticaria, tenderness, epidermal thickening, scaling, and pigmentation). Each symptom was given equal weightage on a specially designed score scale, and each score was rated from minimum score 0 to maximum score 10. The total score was calculated before and after drug treatment.

All adult patients were advised to consume Talekt syrup at a dose of 2 teaspoonful, twice daily, and pediatric patients were advised to consume Talekt syrup at a dose of 1 teaspoonful, twice daily, for a period of 12 weeks.

Follow-up and assessment

Patients were reviewed for 12 weeks and score evaluation was recorded at the end of every 2 weeks and a complete clinical and hematological examination was done at the start and end of the 12th week.

Adverse events

All adverse events, either reported or observed by patients, were recorded with information about severity, date of onset, duration, and action taken regarding the study drug. Relation of adverse events to study medication was predefined as "unrelated" (a reaction that does not follow a reasonable temporal sequence from the administration of the drug), "possible" (follows a known response pattern to the suspected drug, but could have been produced by the patient's clinical state or other modes of therapy administered to the patient), and "probable" (follows a known response pattern to the suspected drug that could not be reasonably explained by the known characteristics of the patient's clinical state).

Patients were allowed to voluntarily withdraw from the study, if they experienced serious discomfort during the study or sustained serious clinical events requiring specific treatment. For patients withdrawing from the study, efforts were made to ascertain the reason for dropout. Non-compliance (defined as failure to take less than 80% of the medication) was not regarded as treatment failure, and reasons for non-compliance were noted.

Primary and secondary endpoints

The predefined primary endpoints were reduction in the mean scores of dermal edema, pruritus, papules, vesicles, urticaria, tenderness, epidermal thickening, and pigmentation. The predefined secondary endpoints were incidences of short- and long-term adverse events and compliance to the drug treatment.

Statistical analysis

Statistical analysis was done according to intention-to-treat principles. Changes in various symptomatic parameters from baseline values and values after 2, 4, 6, 8, 10, and 12 weeks were analyzed by "Wilcoxon Sign Rank test". Investigations done before and after treatment were analysed by Paired Student "t" test. The minimum level of significance was fixed at 95% confidence limit and a 2-sided *p* value of <0.05 was considered significant.

RESULTS

A total of 100 patients were enrolled in the study and 1 patient was lost to follow-up. The mean age of all patients was 20.95 years (SD = 11.95, range = from 3 to 60 years). There were 53 males and 47 females in the study. The mean duration of lesions was 8.79 months. Fifty nine patients had sudden onset of dermatitis and in 41 patients, the onset was gradual.

The mean total score reduced from 10.600 to 7.610, 4.635, 2.320, 0.980, 0.270, and 0.040 (*p*<0.0001) at the end of 2, 4, 6, 8, 10, and 12 week periods, respectively (Table 1 and Figure 1). The mean score for dermal edema reduced from 0.541 to 0.337, 0.133, 0.031, 0.010, 0, and 0 (*p*<0.0001) at the end of 2, 4, 6, 8, 10, and 12 week periods, respectively (Table 1 and Figure 2). The mean score for pruritus reduced from 3.253 to 2.520, 1.677, 0.934, 0.364, 0.091, and 0 (*p*<0.0001) at the end of 2, 4, 6, 8, 10, and 12 week periods, respectively (Table 1 and Figure 3). The mean score for papules reduced from 2.212 to 1.505, 0.854, 0.364, 0.081, 0.010, and 0 (*p*<0.0001) at the end of 2, 4, 6, 8, 10, and 12 week periods, respectively (Table 1 and Figure 4).

Table 1: Reduction in mean symptom score of clinical symptoms of atopic dermatitis with Talekt syrup treatment (Mean ± SEM)

Parameters	Pre-treatment	After treatment (weeks)					
		2	4	6	8	10	12
Total score	10.600 ± 0.296	7.610* ± 0.245	4.635* ± 0.213	2.320* ± 0.150	0.980* ± 0.104	0.270* ± 0.058	0.040* ± 0.024
Dermal edema	0.541 ± 0.093	0.337* ± 0.066	0.133* ± 0.037	0.031* ± 0.018	0.010* ± 0.010	0.000* ± 0.000	0.000* ± 0.000
Pruritus	3.253 ± 0.154	2.520* ± 0.142	1.677* ± 0.128	0.934* ± 0.108	0.364* ± 0.077	0.091* ± 0.032	0.000* ± 0.000
Papules	2.212 ± 0.102	1.505* ± 0.101	0.854* ± 0.091	0.364* ± 0.063	0.081* ± 0.031	0.010* ± 0.010	0.000* ± 0.000
Vesicles	0.788 ± 0.105	0.475* ± 0.075	0.177* ± 0.049	0.080* ± 0.028	0.030* ± 0.017	0.040* ± 0.025	0.010* ± 0.010
Urticaria	2.798 ± 0.194	2.057* ± 0.167	1.338* ± 0.153	0.732* ± 0.109	0.383* ± 0.077	0.121* ± 0.044	0.030* ± 0.023
Tenderness	0.570 ± 0.097	0.291* ± 0.062	0.128* ± 0.040	0.035* ± 0.020	0.035* ± 0.020	0.000* ± 0.000	0.000* ± 0.000
Epidermal thickening	0.100 ± 0.048	0.500* ± 0.030	0.020* ± 0.014	0.000* ± 0.000	0.000* ± 0.000	0.000* ± 0.000	0.000* ± 0.000
Pigmentation	0.300 ± 0.022	0.230* ± 0.084	0.260* ± 0.073	0.170* ± 0.051	0.090* ± 0.032	0.010* ± 0.010	0.000*± 0.000

* $p < 0.0001$ as compared to the pre-treatment value

Table 2: Reduction in levels of hematological values with Talekt syrup treatment (Mean ± SEM)

Parameters	Before treatment	After treatment	Significance
Eosinophils (%)	7.265 ± 0.367	3.046 ± 0.127	$p < 0.0001$; Significant
ESR (mm/hr)	30.78 ± 3.094	18.59 ± 2.844	$p < 0.0001$; Significant
AEC (cells/mm ³)	581.1 ± 25.79	239.2 ± 10.86	$p < 0.0001$; Significant

The mean score for vesicles reduced from 0.788 to 0.475, 0.177, 0.080, 0.030, 0.040, and 0.010 ($p < 0.0001$) at the end of 2, 4, 6, 8, 10, and 12 week periods, respectively (Table 1 and Figure 5). The mean score for urticaria reduced from 2.798 to 2.057, 1.338, 0.732, 0.383, 0.121, and 0.030 ($p < 0.0001$) at the end of 2, 4, 6, 8, 10, and 12 week periods, respectively (Table 1 and Figure 6).

Similarly, the mean score for tenderness reduced from 0.570 to 0.291, 0.128, 0.035, 0.035, 0, and 0 ($p < 0.0001$) at the end of 2, 4, 6, 8, 10, and 12 week periods, respectively (Table 1 and Figure 7). The mean score for epidermal thickening reduced from 0.100 to 0.500, 0.020, 0, 0, 0, and 0 ($p < 0.0001$) at the end of 2, 4, 6, 8, 10, and 12 week periods, respectively (Table 1 and Figure 8). The mean score for pigmentation reduced from 0.300 to 0.230, 0.260,

0.170, 0.090, 0.010, and 0 at the end of 2, 4, 6, 8, 10, and 12 week period respectively (Table 1 and Figure 9).

The mean eosinophil percentage in differential count had significant reduction from the initial value of 7.265 ± 0.367 to 3.046 ± 0.127 after treatment. The mean erythrocyte sedimentation rate (ESR) value reduced significantly from 30.78 ± 3.094 to 18.59 ± 2.844 at the end of treatment. Similarly at the end of treatment, mean absolute eosinophil count (AEC) reduced significantly from 581.1 ± 25.79 to 239.2 ± 10.86 (Table 2 and Figure 10).

There were no clinically significant adverse events reported and observed during the entire study period.

DISCUSSION

Atopic dermatitis is a chronic inflammatory skin disease associated

with cutaneous hyperreactivity to environmental triggers that are innocuous to normal nonatopic individuals. AD is characterized by abnormally increased IgE production⁸. The allergen-induced ligation of IgE on the surface of mast cells induces the release of chemical mediators, such as leukotrienes, histamine or prostaglandins, and causes immediate hypersensitivity reaction, which is followed by a late phase inflammatory reaction involving T cells or eosinophils, leading to the development of atopic eczema⁹.

The mainstay of therapy for AD, including mild to moderate disease, has been the liberal use of emollients and topical corticosteroids while avoiding allergens and other triggers for prevention of flares. Indeed, topical corticosteroids have been the cornerstone of treatment for AD for over 40 years¹⁰.

Figure 1: Reduction in mean symptom score of total score with Talekt syrup treatment

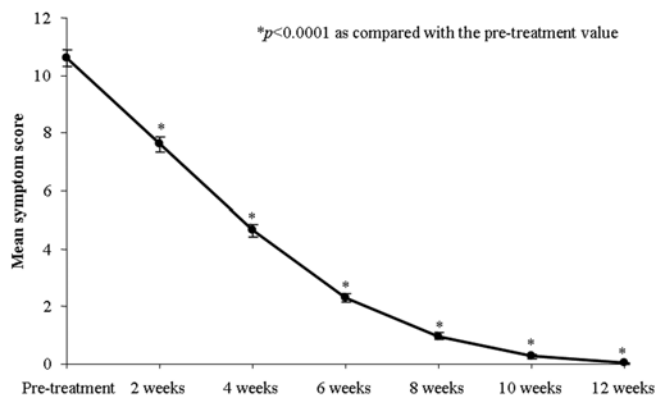


Figure 2: Reduction in mean symptom score of dermal edema with Talekt syrup treatment

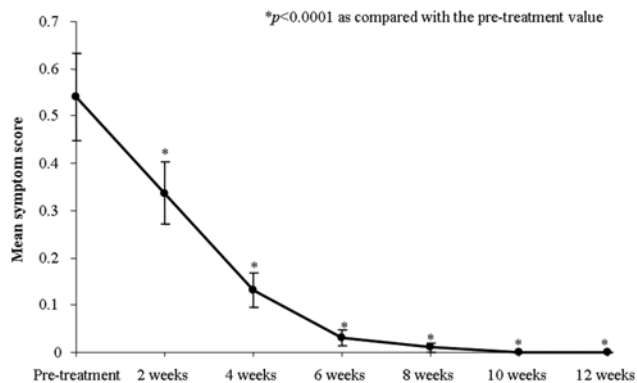


Figure 3: Reduction in mean symptom score of pruritus with Talekt syrup treatment

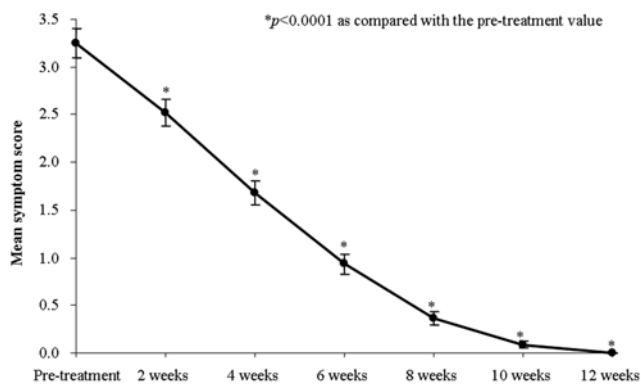


Figure 4: Reduction in mean symptom score of papules with Talekt syrup treatment

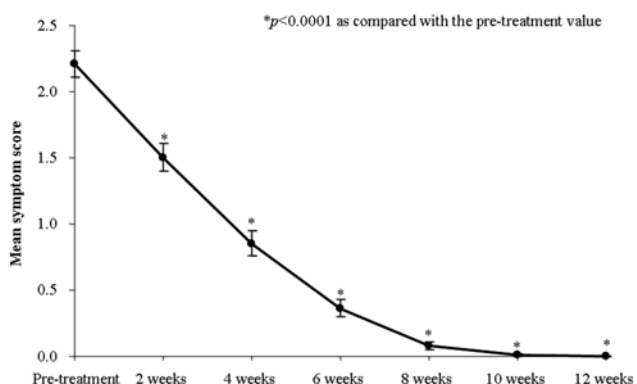


Figure 5: Reduction in mean symptom score of vesicles with Talekt syrup treatment

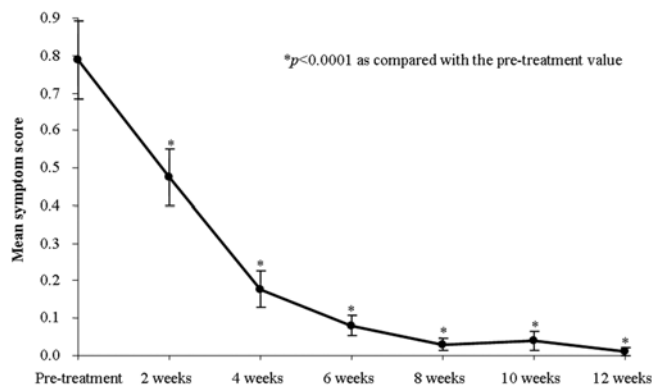


Figure 6: Reduction in mean symptom score of urticaria with Talekt syrup treatment

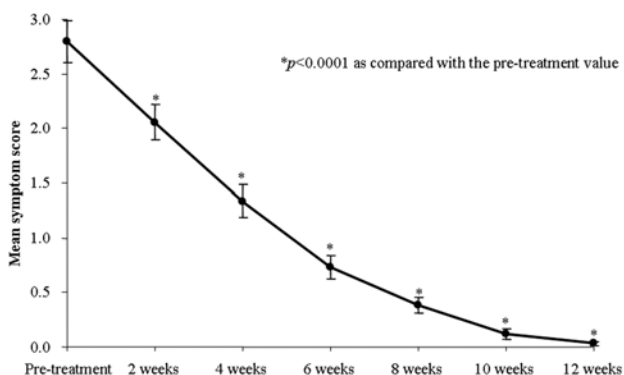


Figure 7: Reduction in mean symptom score of tenderness with Talekt syrup treatment

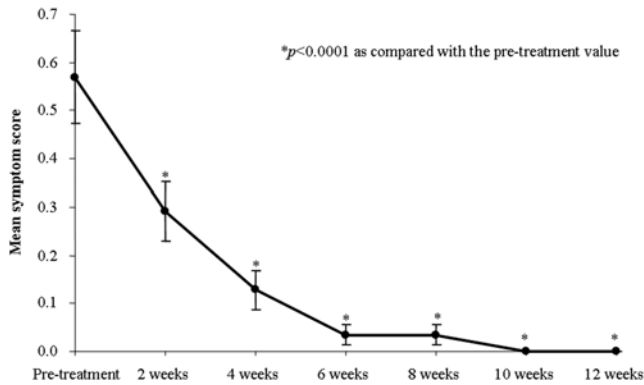


Fig. 8: Reduction in mean symptom score of epidermal thickening with Talekt syrup treatment

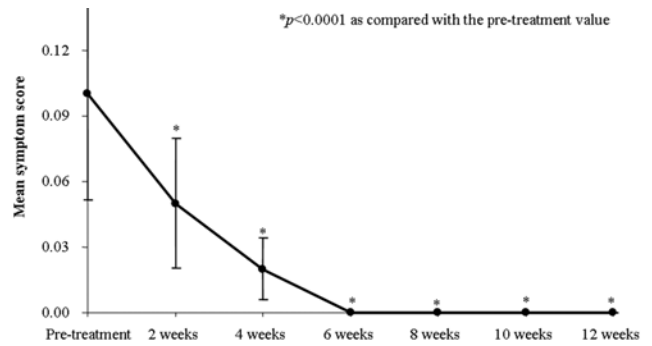


Figure 9: Reduction in mean symptom score of pigmentation with Talekt syrup treatment

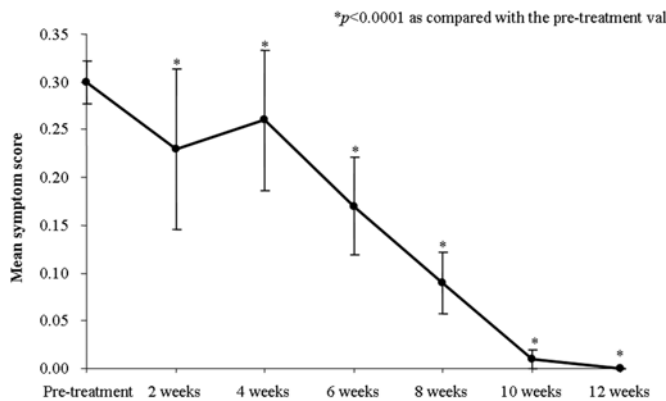
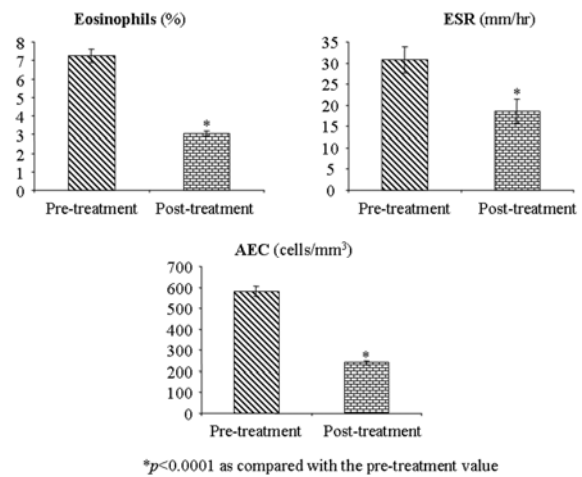


Fig. 10: Reduction in levels of hematological values with Talekt syrup treatment



Topical immunomodulators, antihistamines and antibiotics are also used for the treatment of AD, although severe cases may require systemic corticosteroids, phototherapy with ultraviolet light types A and B (UVA and UVB), and/or immunosuppressants. It is unfortunate that the adverse effects of stronger topical corticosteroids such as striae, atrophy and telangiectasia limit the long-term use of these agents. Moreover, there is a paucity of data to show that the long-term use of topical corticosteroids is without potential systemic effects, especially adverse effects on linear bone growth in children and hypothalamic-pituitary-adrenal axis suppression. When topical corticosteroids are applied to extensive body surface areas (BSAs), they can be absorbed systemically; systemic complications include Cushing's syndrome, adrenal

suppression, loss of bone density, hypertension, cataracts, and growth retardation in children¹¹⁻¹⁴.

The results of the present study showed that there was a significant decrease in the mean score for dermal edema, pruritus, papules, vesicles, urticaria, tenderness, epidermal thickening, and pigmentation at the end of 12-week period. The mean ESR value, mean eosinophil percentage in differential count and mean absolute eosinophil count showed significant reduction after 12 weeks of therapy with Talekt syrup. There were no clinically significant adverse events reported and observed during the entire study period.

The beneficial actions of Talekt syrup might be due to the synergistic actions of its ingredients.

Azadirachta indica has shown activity against various dermatophytes¹⁵. It also has

antibacterial, antisecretory and antihemorrhagic activity¹⁶. Further it is known to act as an immunomodulating, antimetastatic and antioxidant substance^{17,18}.

Tinospora cordifolia has demonstrated broad-spectrum effects on cytokines, autoimmune conditions and chronic degenerative processes¹⁹. It also has potent nitric oxide (NO) scavenging activity and regulates pathological conditions caused by excessive generation of NO and its oxidation product, peroxynitrite²⁰. *Tinospora cordifolia* was also tested for its ability to modulate the changes occurring in the phagocytic activity of peritoneal macrophages after exposure of rats to either carbon tetrachloride or horse serum. It was found to normalize the phagocytic function irrespective to the direction of change, complying to the definition of an adaptogen²¹.

Embelia ribes has potent antibacterial, scavenging (of oxidizing free radicals), and significant wound healing activity²²⁻²⁴. Sawant *et al.*²⁵ have shown that both the ethanol extract as well as the total alkaloids of *Eclipta alba* produce good analgesic activity in all the different models of analgesia used. The immunomodulatory activity of *Eclipta alba* has also been demonstrated²⁶.

Verma and Vinayak²⁷ have shown that oral administration of *Andrographis paniculata* in different doses causes a significant elevation of catalase, superoxide dismutase and glutathione-S-transferase activities, which reveals its antioxidant action. Neoandrographolide, one of the principal diterpene lactones, isolated from *Andrographis paniculata*, was tested to have anti-inflammatory activity²⁸. Treatment of *Andrographis paniculata* significantly elevated the production of interleukin-2 and interferon-gamma in a study done by Sheeja and Kuttan.²⁹ *Andrographis paniculata* showed viricidal activity and antimicrobial activity^{30,31}.

Curcuminoids, a group of phenolic compounds isolated from the roots of *Curcuma longa*, have anti-inflammatory, antioxidant and antimicrobial activities³². Curcumin has been demonstrated to be safe in six human trials and it exerts its anti-inflammatory activity by inhibition of a number of different molecules that play a role in inflammation³³. Hong *et al.*³⁴ demonstrated that the active extract of *Curcuma longa* mediates COX-2 and iNOS inhibitory activities.

Cassia fistula exhibited significant antimicrobial activity and properties that support folkloric use in the treatment of some diseases as broad-spectrum antimicrobial agents³⁵. Along with other activities, such as antitumor, antioxidant, hypoglycemic, hepatoprotective, antibacterial, hypocholesterolemic, and antidiabetic activities, the healing potential of *Cassia fistula* provides a scientific rationale for the traditional use of this plant in the management of infected dermal wound³⁶.

The immunomodulatory activity of Triphala (*Terminalia chebula*, *Terminalia bellirica* and *Emblia*

officinalis) has been demonstrated in a study done by Srikumar *et al.*³⁷ Triphala has promising antioxidant and anti-inflammatory activities^{38,39}. Kumar *et al.*⁴⁰ showed the antibacterial, wound healing and antioxidant activities of Triphala ointment, necessary for the management of infected wounds.

CONCLUSION

Atopic dermatitis is a commonly encountered syndrome in medical practice. Being a multifactorial syndrome complex, many therapeutic interventions have been studied. However, there is no clinically effective and safe medication that can be recommended in the management of AD. This study was conducted to evaluate the clinical efficacy and safety of Talekt syrup in AD.

This study observed a significant reduction in the mean score for dermal edema, pruritus, papules, vesicles, urticaria, tenderness, epidermal thickening, and pigmentation at the end of 12-week period. There were no clinically significant adverse events, either reported or observed, during the entire study period. Therefore, it may be concluded that Talekt syrup is clinically safe and effective in the management of atopic dermatitis.

REFERENCES

- Leung DY, and Bieber T. Atopic dermatitis. *Lancet* 2003;361:151-160.
- Kay J, Gawkrödger DJ, Mortimer MJ, and Jaron AG. The prevalence of childhood atopic eczema in a general population. *J. Am. Acad. Dermatol.* 1994;30:35-39.
- Larsen FS, and Hanifin JM. Epidemiology of atopic dermatitis. *Immunol. Allergy Clin. North Am.* 2002;22:1-24.
- Rudikoff D, and Lebwohl M. Atopic dermatitis. *Lancet* 1998;351:1715-1721.
- Ahuja A, Land K, and Barnes CJ. Atopic dermatitis. *South Med. J.* 2003;96:1068-1072.
- Castro APBM. *Dermatite atópica*. In: Grumach AS, (Ed.), *Alergia e imunologia na infância e na adolescência*, 1a ed. São Paulo: Atheneu. 2002: pp. 185-201.
- Boguniewicz M, Leung DY. *Atopic Dermatitis*. In: Middleton's. *Allergy Principles & Practice*, Saint Louis: Mosby; 2003: 6th Edn., pp. 1559-1580.
- Leung DYM. Atopic dermatitis: The skin as a window into the pathogenesis of chronic allergic diseases. *J. Allergy Clin. Immunol.* 1995;96:302-318.
- Werfel S, Massey W, Lichtenstein LM and Bochner BS. Preferential recruitment of activated, memory T lymphocytes into skin chamber fluids during human cutaneous late-phase allergic reactions. *J. Allergy Clin. Immunol.* 1995;96:57-65.
- Hanifin JM, Cooper KD, Ho VC, et al. Guidelines of care for atopic dermatitis, developed in accordance with the American Academy of Dermatology (AAD)/American Academy of Dermatology Association "Administrative Regulations for Evidence-Based Clinical Practice Guidelines. *J. Am. Acad. Dermatol.* 2004;50:391-404.
- Castanedo-Cazares JP, Lopez-Lucio RH, and Moncada B. Cushing syndrome following the prescription of antifungal, antibiotic, corticosteroid cream. *Int. J. Dermatol.* 2003;42:318.
- Ermis B, Ors R, Tastekin A, and Ozkan B. Cushing's syndrome secondary to topical corticosteroids abuse. *Clin. Endocrinol.* 2003;58:795-796.
- Aalto-Korte K, and Turpeinen M. Bone mineral density in patients with atopic dermatitis. *Br. J. Dermatol.* 1997;136(2):172-175.

- Walker BR, Best R, Shackleton CHL, Padfield LP, and Edwards CRW. Increased vasoconstrictor sensitivity to glucocorticoids in essential hypertension. *Hypertension* 1996;27:190-196.
- Natarajan V, Venugopal PV, and Menon T. Effect of *Azadirachta indica* (neem) on the growth pattern of dermatophytes. *Indian J. Med. Microbiol.* 2003;21(2): 98-101.
- Thakurta P, Bhowmik P, Mukherjee S, Hajra TK, Patra A, and Bag PK. Antibacterial, antisecretory and antihemorrhagic activity of *Azadirachta indica* used to treat cholera and diarrhea in India. *J. Ethnopharmacol.* 2007;111(3):607-612.
- Beuth J, Schneider H, and Ko HL. Enhancement of immune responses to neem leaf extract (*Azadirachta indica*) correlates with antineoplastic activity in BALB/c-mice. *In Vivo* 2006;20(2):247-251.
- Sithisarn P, Supabphol R, and Gritsanapan W. Antioxidant activity of Siamese neem tree (VP1209). *J. Ethnopharmacol.* 2005;99(1):109-112.
- Spelman K, Burns J, Nichols D, Winters N, Ottersberg S, and Tenborg M. Modulation of cytokine expression by traditional medicines: A review of herbal immunomodulators. *Altern. Med. Rev.* 2006;11(2):128-150.
- Jagetiya GC, and Baliga MS. The evaluation of nitric oxide scavenging activity of certain Indian medicinal plants *in vitro*: A preliminary study. *J. Med. Food* 2004;7(3): 343-348.
- Rege NN, Thatte UM, and Dahanukar SA. Adaptogenic properties of six rasayana herbs used in Ayurvedic medicine. *Phytother. Res.* 1999;13(4):275-279.
- Chitra M, Devi CS, and Sukumar E. Antibacterial activity of embelin. *Fitoterapia* 2003;74(4):401-403.
- Kumara Swamy HM, Krishna V, Shankarmurthy K, Abdul Rahiman B, Mankani KL, et al. Wound healing activity of embelin isolated from the ethanol extract of leaves of *Embelia ribes*. *J. Ethnopharmacol.* 2007;109(3):529-534.
- Joshi R, Kamat JP, and Mukherjee T. Free radical scavenging reactions and antioxidant activity of embelin: Biochemical and pulse radiolytic studies. *Chem. Biol. Interact.* 2007;167(2):125-134.
- Sawant M, Isaac JC, and Narayanan S. Analgesic studies on total alkaloids and alcohol extracts of *Eclipta alba* (Linn.) Hassk. *Phytother. Res.* 2004;18(2):111-113.
- Jayathirtha MG, and Mishra SH. Preliminary immunomodulatory activities of methanol extracts of *Eclipta alba* and *Centella asiatica*. *Phytomed.* 2004;11(4):361-365.
- Verma N, and Vinayak M. Antioxidant action of *Andrographis paniculata* on lymphoma. *Mol. Biol. Rep.* 2007;Sep. 5.
- Liu J, Wang ZT, and Ji LL. *In vivo* and *in vitro* anti-inflammatory activities of neoandrographolide. *Am. J. Chin. Med.* 2007;35(2):317-328.
- Sheeja K, and Kuttan G. Modulation of natural killer cell activity, antibody-dependent cellular cytotoxicity, and antibody-dependent complement-mediated cytotoxicity by andrographolide in normal and Ehrlich ascites carcinoma-bearing mice. *Integr. Cancer Ther.* 2007;6(1):66-73.
- Wiarat C, Kumar K, Yusof MY, Hamimah H, Fauzi ZM, and Sulaiman M. Antiviral properties of ent-labdene diterpenes of *Andrographis paniculata* nees, inhibitors of herpes simplex virus type 1. *Phytother. Res.* 2005;19(12):1069-1070.
- Singha PK, Roy S, and Dey S. Antimicrobial activity of *Andrographis paniculata*. *Fitoterapia* 2003;74(7-8):692-694.
- Joe B, Vijaykumar M, Lokesh BR. Biological properties of curcumin-cellular and molecular mechanisms of action. *Crit. Rev. Food Sci. Nutr.* 2004;44(2):97-111.
- Chainani-Wu N. Safety and anti-inflammatory activity of curcumin: A component of tumeric (*Curcuma longa*). *J. Altern. Complement Med.* 2003; 9(1): 161-168.
- Hong CH, Hur SK, Oh OJ, Kim SS, Nam KA, and Lee SK. Evaluation of natural products on inhibition of inducible cyclooxygenase (COX-2) and nitric oxide synthase (iNOS) in cultured mouse macrophage cells. *J. Ethnopharmacol.* 2002;83(1-2):153-159.
- Kumar VP, Chauhan NS, Padh H, and Rajani M. Search for antibacterial and antifungal agents from selected Indian medicinal plants. *J. Ethnopharmacol.* 2006;107(2): 182-188.
- Senthil Kumar M, Sriprya R, Vijaya Raghavan H, and Sehgal PK. Wound healing potential of *Cassia fistula* on infected albino rat model. *J. Surg. Res.* 2006;131(2): 283-289.
- Srikumar R, Jeya Parthasarathy N, Sheela and Devi R. Immunomodulatory activity of triphala on neutrophil functions. *Biol. Pharm. Bull.* 2005;28(8):1398-1403.
- Naik GH, Priyadarshini KI, Bhagirathi RG, Mishra B, Mishra KP, et al. *In vitro* antioxidant studies and free radical reactions of triphala, an ayurvedic formulation and its constituents. *Phytother. Res.* 2005;19(7):582-586.
- Rasool M, and Sabina EP. Antiinflammatory effect of the Indian Ayurvedic herbal formulation Triphala on adjuvant-induced arthritis in mice. *Phytother. Res.* 2007;21(9): 889-894.
- Kumar MS, Kirubanandan S, Sriprya R, and Kumar Sehgal P. Triphala Promotes Healing of Infected Full-Thickness Dermal Wound. *J. Surg. Res.* 2007 Jul 26. [Epub ahead of print].

